

## RESEARCH HIGHLIGHT

# Androgen receptor and intracrine androgen signaling in endometrial carcinomas

Yasuhiro Miki<sup>1</sup>, Misaki Fue<sup>1</sup>, Kiyoshi Takagi<sup>2</sup>, Chiaki Hashimoto<sup>1,3</sup>, Sota Tanaka<sup>1,3</sup>, Takashi Suzuki<sup>2</sup>, Kiyoshi Ito<sup>1</sup>

<sup>1</sup>Department of Disaster Obstetrics and Gynecology, International Research Institute of Disaster Science (IRIDeS), Tohoku University, Sendai, 980-8575 Japan

<sup>2</sup>Department of Pathology and Histotechnology, Tohoku University Graduate School of Medicine, Sendai, 980-8575 Japan

<sup>3</sup>Department of Obstetrics and Gynecology, Tohoku University Graduate School of Medicine, Sendai, 980-8575 Japan

Correspondence: Yasuhiro Miki

E-mail: miki@patholo2.med.tohoku.ac.jp

Received: May 27, 2015

Published online: July 08, 2015

The androgen receptor (AR) is known to play critical roles in the malignancy of prostate cancer as well as the management of male reproductive organs. Endometrial carcinoma, one of the major female cancers, is considered an androgen-related cancer. However, the importance of androgen signaling through its receptor in endometrial carcinomas has not yet been clarified. We recently demonstrated the significance of androgen signaling and intracrine dihydrotestosterone (DHT) in endometrial carcinomas as follows: 1) A positive status of androgen receptor (AR) was significantly associated with high rates of progression-free survival (PFS), but not with endometrial cancer-specific survival (ECSS) in endometrial carcinoma patients; 2) The potent androgen DHT was synthesized from testosterone by 5 $\alpha$ -reductase in endometrial carcinoma tissues; and 3) endometrial carcinoma patients that were AR/5 $\alpha$ -reductase type 1 double-negative had significantly worse PFS and ECSS. These findings suggest that androgen signaling exerts anti-cancer effects through the intratumoral DHT-AR pathway in endometrial carcinomas. In this highlight article, we describe androgen signaling in endometrial carcinomas, focusing mainly on our recent study entitled “The role of 5 $\alpha$ -reductase type 1 associated with intratumoral dihydrotestosterone concentrations in human endometrial carcinoma” and discuss the findings of some previous related studies.

**Keywords:** Androgen receptor; 5 $\alpha$ -reductase; Intracrine; Endometrial cancer

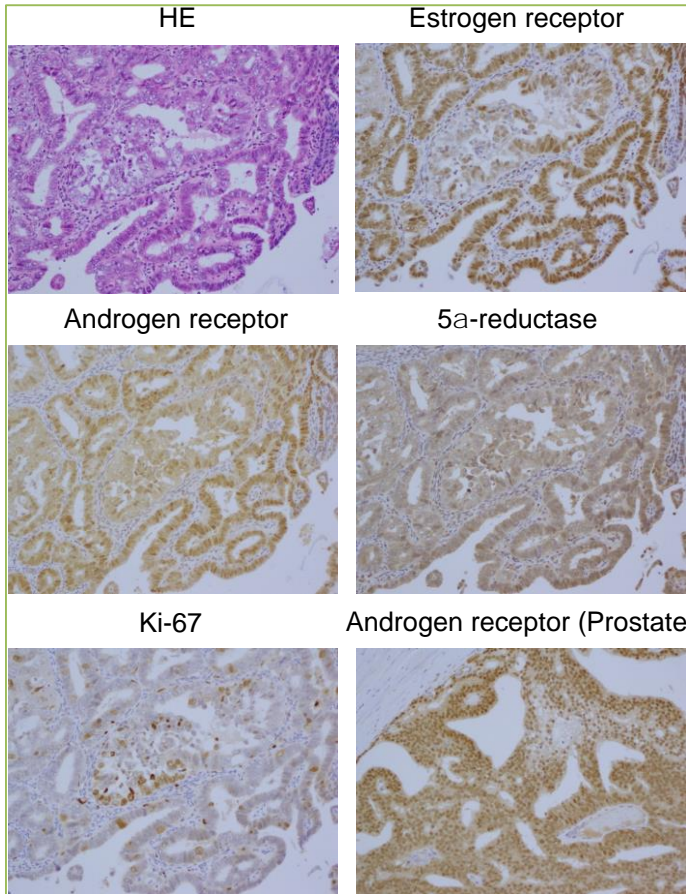
**To cite this article:** Yasuhiro Miki, et al. Androgen receptor and intracrine androgen signaling in endometrial carcinomas. Receptor Clin Invest 2015; 2: e853. doi: 10.14800/rci.853.

## Introduction

Endometrial cancer is one of the most common types of cancer of the uterus. It occurs in the endometrium, which is formed by the epithelial cells of the uterine body (corpus uteri). Endometrial carcinoma is divided into two types, termed Types I and II, by histology and epidemiology. Approximately 70-80% of endometrial cancer patients have Type I carcinomas, which are known to be low-grade endometrioid tumors, such as G1 and G2, with a good clinical prognosis<sup>[1,2]</sup>. Another 20% of patients have Type II

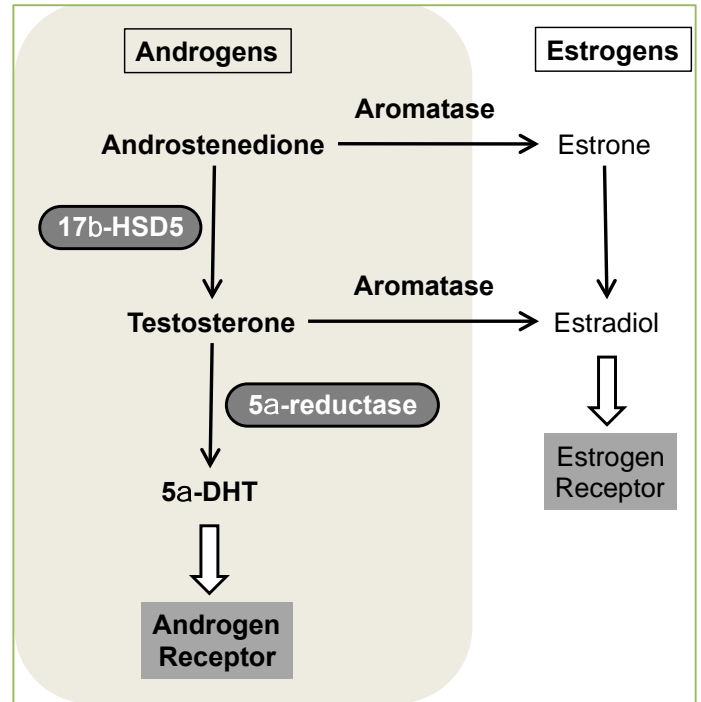
carcinomas, which are high-grade tumors, including G3 endometrioid tumors and serous carcinomas that have a poor clinical prognosis<sup>[1]</sup>. The results from epidemiological, clinical, and pathological analyses suggest that Type I endometrial carcinomas are induced by excess estrogen<sup>[3]</sup>. Many studies have demonstrated the expression of estrogen receptor (ER) in Type I endometrial carcinomas<sup>[4-6]</sup>.

Androgen, known as the male hormone, plays a critical role in the development of organs in the male genital tract, such as the testes and prostate, and their reproductive



**Figure 1. Immunohistochemistry of hormone-related factors in endometrial carcinomas.** Estrogen receptor ( $\alpha$ ), androgen receptor, and Ki-67 were detected in the nuclei of endometrial carcinoma cells. 5 $\alpha$ -reductase type 1 was detected in the cytoplasm of endometrial carcinoma cells. Prostate carcinoma tissues are shown as a positive control. HE, hematoxylin and eosin stain; Prostate, prostate carcinoma.

activities. It exerts these hormonal activities by binding to the specific androgen receptor (AR). AR, also named the nuclear receptor subfamily 3 group C gene 4 (NR3C4), belongs to the nuclear receptor superfamily for steroid hormones. The significance of AR in pathological conditions, especially in prostate cancer, has been established. In addition, breast cancer is known as a representative estrogen-dependent tumor, and estrogen participates greatly in cancer progress. AR is also expressed in a majority of postmenopausal breast carcinoma tissues, suggesting important roles for androgens in breast cancer as well as estrogen in cancer progression<sup>[7-9]</sup>. Immunohistochemistry of ER and AR in endometrial carcinoma tissues is shown in Figure 1. Endometrial cancer is the major malignant tumor in women and it is known, similar to breast cancer, as an estrogen-dependent tumor. In this research highlight, we have reviewed our recent report regarding intratumoral androgen synthesis and the significance of androgen signaling in endometrioid endometrial carcinoma tissues.



**Figure 2. Summary of intracrine androgen and estrogen signaling.** 5 $\alpha$ -dehydrotestosterone has a higher affinity to androgen receptor than testosterone. 17 $\beta$ -HSD5, 17 $\beta$ -hydroxysteroid dehydrogenase type 5; 5 $\alpha$ -DHT, 5 $\alpha$ -dehydrotestosterone.

### Intracrine androgen signaling

“Paracrine” signaling is a form of cell signaling wherein hormones are released from endocrine cells and affect nearby targeting cells. On the other hand, in “autocrine” signaling, hormones act directly on the hormone-releasing cells themselves. In addition, intratissuelar or *in situ* synthesis of hormones from circulating biologically inactive or weak precursors into active hormones in the target tissue is known as “intracrine” signaling<sup>[9, 11]</sup>. The intracrine function of sex steroid hormones has been known to play an important role in hormone-dependent tumors such as breast, prostate, and endometrial cancers<sup>[9, 11]</sup>. The intracrine pathway of androgen and estrogen in breast carcinoma tissues is summarized in Figure 2<sup>[7, 9]</sup>. Androstenedione, which has weak androgenic action, is synthesized in both the testes and ovaries. In addition, the adrenal cortex is well known as a major androstenedione-producing organ in females. The hormone 17 $\beta$ -hydroxysteroid dehydrogenase type 5 (17 $\beta$ -HSD5), also known as AKR1C3, contributes to converting circulating androstenedione into testosterone at target tissues<sup>[12]</sup>. Then, testosterone is converted into the most potent androgen, dihydrotestosterone (DHT), through the enzymatic activity of 5 $\alpha$ -reductase located in target tissues<sup>[13]</sup>.

## Significance of androgen receptors in endometrial carcinomas

In the results from our previous immunohistochemical analysis, the AR protein was localized predominantly in normal endometrial stromal cells in the proliferative phase and in epithelial cells in the secretory phase of the menstrual cycle [14]. In 44 endometrial carcinoma cases, AR protein evaluated by immunohistochemistry was shown in the nuclei of carcinoma cells and the proportion positive was 88.6% [14]. Maia *et al.* [15] reported that the rate of AR-positive cells was higher in ER-positive endometrial endometrioid cancers than in ER-negative endometrial cancers such as serous and clear-cell carcinomas. Several studies, including Maia's, have suggested that AR signaling may modulate cancer progression, including cell proliferation and invasion in endometrial cancers [15, 16]. Androgen has been known to inhibit cell proliferation directly in endometrial cancers *in vitro* [17, 18]. Otherwise, immunohistochemical analysis has demonstrated that a positive correlation between progesterone receptor and bcl-2 and an inverse correlation between ER and bax in endometrial carcinomas [19]. However, there were no correlations between AR and apoptosis markers such as bcl-2, bax, and bcl-x [19]. Therefore, further studies into the correlation between AR expression and clinicopathological parameters to clarify the clinical significance of androgen in endometrial carcinomas were needed. In our recent study using 86 endometrioid tissues, an AR-positive status was inversely correlated with the malignancy of a tumor, represented by histological grade, lymphovascular invasion, and the Ki-67 (demonstrated by immunohistochemistry shown in Figure 1) and positively correlated with ER expression [20]. Ki-67 is a pathological cell proliferation marker that is detected at active phases of the cell cycle, but not in quiescent cells. In addition, an AR-positive status was significantly associated with better progression-free survival (PFS), but not significantly associated with endometrial cancer-specific survival (ECSS) in 86 endometrioid patients [20].

### Intracrine androgen signaling in endometrial carcinomas

In 2002, we first reported the expression of the 5 $\alpha$ -reductase type 1 (Figure 1) and type 2 in endometrioid endometrial adenocarcinoma tissue and normal endometrium by immunohistochemistry [14]. In the normal human endometrium, immunoreactivities to both 5 $\alpha$ -reductase types 1 and 2 were detected in the cytoplasm of epithelial cells in the proliferative and secretory phases of the menstrual cycle [14]. In endometrial carcinomas, immunoreactivities to 5 $\alpha$ -reductase types 1 and type 2 were detected in the cytoplasm of parenchymal cells and the percentages positive were 84.1% and 77.3% for 5 $\alpha$ -reductase type 1 and type 2, respectively, in the 44 cases examined [14]. These findings suggested that androgen signaling exerts some effect on

Table 1. The median tissue and serum concentration ratio of testosterone and DHT in the 31 endometrial cancer and 5 normal endometrial tissues.

	Normal (n=5)	Endometrial cancer (n=31)	Fold change
Testosterone	0.32	0.42	1.3
DHT	0.08	0.63	7.9

endometrial carcinoma cells. However, in this previous study, the relationship between androgen-related factors described above and patients' prognosis remained unclear. Furthermore, the intratumoral androgen concentration in endometrial carcinoma tissues had not been examined conventionally. Therefore, we recently reported how androgens are synthesized in intratumoral endometrial carcinoma tissues [20]. Although radioimmunoassay (RIA) and enzyme-linked immunosorbent assay (ELISA) have been employed as standard methods of measurement for steroid hormones, these methods have some problems, including the need for disposal of radiolabeled wastes, sensitivity, and specificity/cross-reactions [21]. Alternatively, liquid chromatography electrospray ionization tandem mass spectrometry (LC-MS/MS) makes it possible to measure highly specific hormones from very small sample amounts [21]. Therefore, in this study, we first measured both the tissue and serum concentrations of androgen by LC-MS/MS in 31 patients. The median tissue and serum concentration ratios of testosterone and DHT in the 31 endometrial cancer tissues are summarized in Table 1 [20]. These results from the LC-MS/MS analysis demonstrated the intratumoral synthesis of DHT in endometrial cancer tissues [20]. Furthermore, we first found that 5 $\alpha$ -reductase type 1, evaluated by immunohistochemistry, was associated with intratumoral DHT concentrations in endometrial carcinoma tissues [20].

In our 2015 study, although an AR-positive status was not found to be significantly associated with ECSS in the 86 endometrioid patients described above, the group of patients that were positive for 5 $\alpha$ -reductase type 1 had a significantly better prognosis than the negative group for both PFS and ECSS [20]. We then divided these patients into four groups according to their statuses of AR and 5 $\alpha$ -reductase type 1, such as AR/5 $\alpha$ -reductase type 1 double positive, double negative, positive/negative, and negative/positive, respectively. An AR/5 $\alpha$ -reductase type 1 double negative status was significantly associated with a worse PFS and ECSS in the 86 endometrioid patients [20]. Therefore, it is important to evaluate both the 5 $\alpha$ -reductase type 1, which is surrogate marker of intratumoral DHT concentration, and the AR status to know the effect of androgenic signaling on cancer progression in endometrial cancers.



## Conclusions

Several reports on endometrial cancers, including our own studies, have demonstrated the significance of androgen signaling through the AR on anti-cancer progression. AR expression is known to be downregulated by hypermethylation of the AR gene CpG islands in endometrial cancers but not in normal endometria<sup>[22]</sup>. Collectively, these reports suggest that androgen therapy may be effective on endometrial cancers. However, the downstream signals of AR, which are directly correlated with anti-cancer progression, remain unclear. Further examinations into the mechanisms of anti-cancer signaling by AR-activation are required to establish the potential for androgen therapies for endometrial cancer patients.

## Conflicting interests

The authors declare that there are no conflicts of interests.

## Acknowledgements

This research was supported by Tohoku University IRIDeS Research Project (Y.M. and K.I.). We thank Cactus Communications Inc. (Tokyo, Japan) who provided language editing.

## References

- DeLair D. Chapter 2 Pathology of Gynecologic Cancer. In Management of Gynecological Cancers in Older Women. Edited by Lichtman SM, Audisio RA. Springer-Verlag London 2013; 21-38.
- da Silva JL, Paulino E, Dias MF, de Melo AC. Endometrial cancer: redefining the molecular-targeted approach. *Cancer Chemother Pharmacol* 2015 in press.
- Kounelis S, Kapranos N, Kouri E, Coppola D, Papadaki H, Jones MW. Immunohistochemical profile of endometrial adenocarcinoma: a study of 61 cases and review of the literature. *Mod Pathol* 2000; 13:379-388.
- Ito K, Utsunomiya H, Niikura H, Yaegashi N, Sasano H. Inhibition of estrogen actions in human gynecological malignancies: new aspects of endocrine therapy for endometrial cancer and ovarian cancer. *Mol Cell Endocrinol* 2011; 340:161-167.
- Ito K, Utsunomiya H, Yaegashi N, Sasano H. Biological roles of estrogen and progesterone in human endometrial carcinoma--new developments in potential endocrine therapy for endometrial cancer. *Endocr J* 2007; 54:667-679.
- Gibson DA, Simitsidellis I, Collins F, Saunders PT. Evidence of androgen action in endometrial and ovarian cancers. *Endocr Relat Cancer* 2014; 21:T203-218.
- Miki Y, Suzuki T, Sasano H. Intracrinology of sex steroids in ductal carcinoma in situ (DCIS) of human breast: comparison to invasive ductal carcinoma (IDC) and non-neoplastic breast. *J Steroid Biochem Mol Biol* 2009; 114:68-71.
- Suzuki T, Miki Y, Takagi K, Hirakawa H, Moriya T, Ohuchi N, et al. Androgens in human breast carcinoma. *Med Mol Morphol* 2010; 43:75-81.
- Sasano H, Suzuki T, Miki Y, Moriya T. Intracrinology of estrogens and androgens in breast carcinoma. *J Steroid Biochem Mol Biol* 2008; 108:181-185.
- Suzuki T, Miki Y, Ohuchi N, Sasano H. Intratumoral estrogen production in breast carcinoma: significance of aromatase. *Breast Cancer* 2008;15:270-277.
- Sasano H, Harada N. Intratumoral aromatase in human breast, endometrial, and ovarian malignancies. *Endocr Rev* 1998; 19:593-607.
- Penning TM, Burczynski ME, Jez JM, Lin HK, Ma H, Moore M, Ratnam K, et al. Structure-function aspects and inhibitor design of type 5 17beta-hydroxysteroid dehydrogenase (AKR1C3). *Mol Cell Endocrinol* 2001;171:137-149.
- Killian J, Pratis K, Clifton RJ, Stanton PG, Robertson DM, O'Donnell L. 5alpha-reductase isoenzymes 1 and 2 in the rat testis during postnatal development. *Biol Reprod* 2003; 68:1711-1718.
- Ito K, Suzuki T, Akahira J, Moriya T, Kaneko C, Utsunomiya H, et al. Expression of androgen receptor and 5alpha-reductases in the human normal endometrium and its disorders. *Int J Cancer* 2002; 99:652-657.
- Maia H Jr, Maltez A, Fahel P, Athayde C, Coutinho E. Detection of testosterone and estrogen receptors in the postmenopausal endometrium. *Maturitas* 2001; 38:179-188.
- Horie K, Takakura K, Imai K, Liao S, Mori T. Immunohistochemical localization of androgen receptor in the human endometrium, decidua, placenta and pathological conditions of the endometrium. *Hum Reprod* 1992; 7:1461-1466.
- Centola GM. Inhibition of endometrial carcinoma cell cultures by a synthetic androgen. *Cancer Res* 1985; 45:6264-6267.
- Hackenberg R, Schulz KD. Androgen receptor mediated growth control of breast cancer and endometrial cancer modulated by antiandrogen- and androgen-like steroids. *J Steroid Biochem Mol Biol* 1996; 56:113-117.
- Bozdoğan O, Atasoy P, Ereku S, Bozdoğan N, Bayram M. Apoptosis-related proteins and steroid hormone receptors in normal, hyperplastic, and neoplastic endometrium. *Int J Gynecol Pathol* 2002; 21:375-382.
- Tanaka S, Miki Y, Hashimoto C, Takagi K, Doe Z, Li B, et al. The role of 5α-reductase type 1 associated with intratumoral dihydrotestosterone concentrations in human endometrial carcinoma. *Mol Cell Endocrinol* 2015; 401:56-64.
- Rauh M. LC-MS/MS for protein and peptide quantification in clinical chemistry. *J Chromatogr B Analyt Technol Biomed Life Sci* 2012; 883-884:59-67.
- Sasaki M, Oh BR, Dharia A, Fujimoto S, Dahiya R. Inactivation of the human androgen receptor gene is associated with CpG hypermethylation in uterine endometrial cancer. *Mol Carcinog* 2000; 29:59-66.